Growth Analysis of Individual Abdominal Atherosclerotic Calcified Deposits

L. Lillemark[2], M. Ganz[1] and M. Nielsen[1]
[1]Nordic Bioscience Imaging, Herlev, Denmark, [2]Department of Computer Science, University of Copenhagen

Introduction:

Abdominal calcifications can be used as a clinical indicator of atherosclerosis and can predict atherosclerotic plaques in the coronary ateries.
In this study we have looked at the development of the individual abdominal atherosclerotic calcifications (AACs) over time based on lateral X-rays of the lumbar section L1-L4.

We have made a TPS registration of the aortas from follow-up to baseline, thereby aligning the calcifications. Now we can match the AACs based on area overlap. From one-to-one corresponding calcifications we have derived geometric measurements that describe the growth over time.

The calcifications were aligned to an idealised aorta coordinate system to be able to describe the growth patterns in an intuitive anatomical direction.

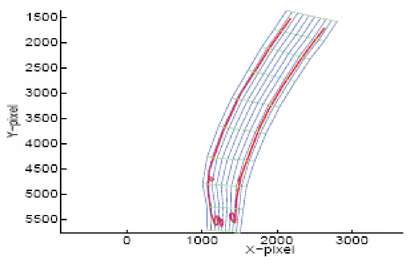

Figure 1: An example of the idealised aorta coordinate system, that is used for calculating the growth patterns along the aorta.

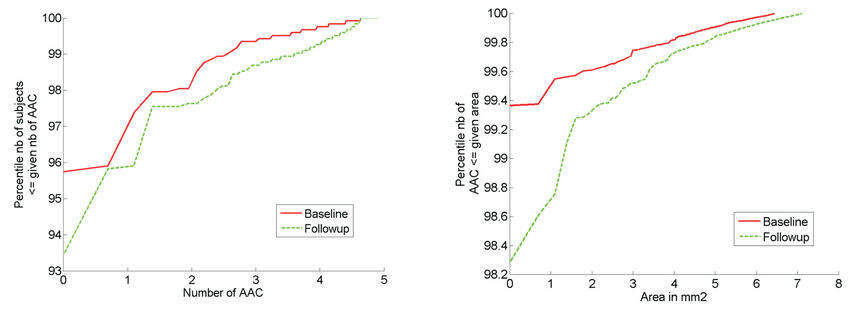

(a) (b)

Figure 2: (a) The percentile of number of subjects with <= number of AACs (b) The percentile number of AACs >= area. Note that the number of AACs increases, and the size of the AACs also increases, indicating that the growth of AACs could give new infomation about the progression of atherosclerosis.

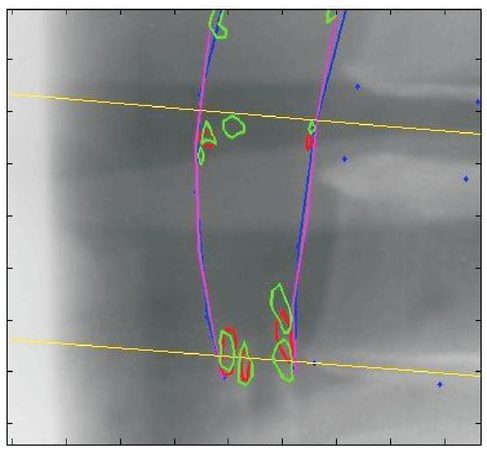

Figure 3: An example of some matched calcifications. Blue is representing the baseline annotations, magenta represet the follow-up aorta, red the baseline calcifications and green the follow-up calcifications. The TPS registration is based on the intersections between the aortas and the intervertebrae lines shown in yellow.

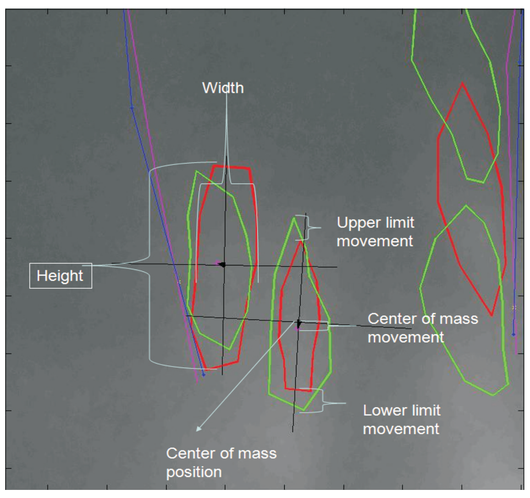

Figure 4: An example of the growth patterns. Red represents baseline AACs, green follow-up AACs. The height, width, center of mass (CM) and the movement of the CM are outlined. The black lines correspond to the axes in the idealised aorta coordinate system.

The Data:

The data set consists of 103 women with the lumber aorta visible in a single radiograph and AACs present at both baseline and follow-up. The images were taken at 1992-93 (baseline) and again in 2000-02 (follow-up).

Results:

We were able to match 35.7 % of the AACs as one-to-one corresponding calcifications. The inter/intra observer variability is 50-60 % based on three trained blinded radiologist.
The AACs grew longitudinally, indicating that they will occupy more of the aorta wall. The AACs grew downstream the aorta, which could be observed by a downwards shift of the CM.
The calcifications grew mostly in the L3-L4 region and were also more aligned to the posterior aorta wall.

Table 1: The average growth patterns for all and matched baseline and follow-up AACs and their growth. (*=p<0.05 **=p<0.01, ***=p<0.001)

	All Baseline	All Follow-up	Matched Baseline	Matched Follow-up	Growth in %
Width (mm)	2.25 (± 1.29)	2.30 (± 1.67)	2.37 (± 1.33)	2.87 (± 1.16)***	21 % (± 22 %)***
Height (mm)	5.07 (± 3.84)	6.13 (± 6.76)	6.11 (± 3.95)***	8.61 (± 5.34)***	41 % (± 35 %)***
Area (mm^2)	171 (± 200)	203 (± 300)	211 (± 224)*	329 (± 329)***	57 % (± 34 %)***

	The movement
CY (mm)	0.60 (± 2.69)***
CX - posterior (n=161) (mm)	0.03 (± 0.98)
CX - anterior (n=73) (mm)	0.10 (± 0.96)
Lower limit (mm)	1.85 (±3.69)***
Upper limit (mm)	"-0.59 (±3.55)

Table 2: The movement of the center of mass downwards (CY) and to the side (CX) and the movement in the upper andlower limit. Note how the calcifications move downward the aorta.

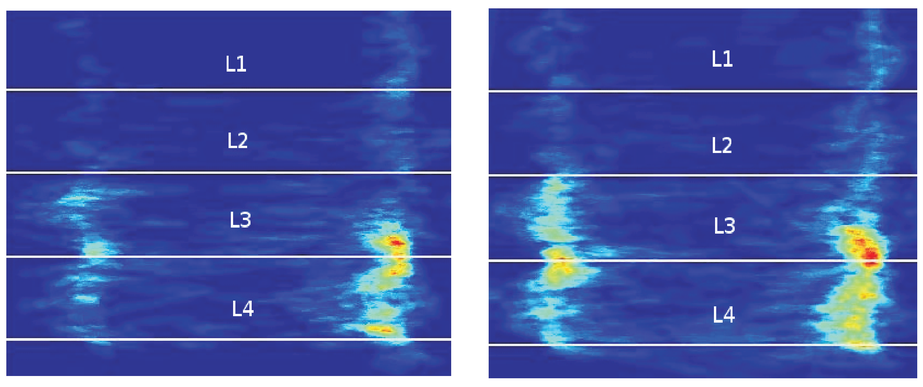

(a) (b)

Figure 3: The distribution of the calcifications at baseline (a) and follow-up (b). Note how the AACs were aligned at the L3-L4 and also more clusered at the posterior aorta wall.

Conclusions:

- **The growth along the aorta wall indicates a stiffening of the aorta wall.**
- **The AACs grew downward the blood stream, which could be caused by the turbulence in the blood flow.**
- **The calcifications grew significantly from baseline to follow-up indicating that a growth analysis of the individual calcifications could provide new insight into the disease progression.**